



Medica

UTILIZATION MANAGEMENT POLICY

TITLE: LUMBAR SPINE SURGERIES

EFFECTIVE DATE: January 15, 2024

This policy was developed with input from specialists in orthopedic spine surgery and endorsed by the Medical Policy Committee.

IMPORTANT INFORMATION – PLEASE READ BEFORE USING THIS POLICY

These services may or may not be covered by all Medica plans. Coverage is subject to requirements in applicable federal or state laws. Please refer to the member's plan document for other specific coverage information. If there is a difference between this general information and the member's plan document, the member's plan document will be used to determine coverage. With respect to Medicare, Medicaid, and other government programs, this policy will apply unless these programs require different coverage. Members may contact Medica Customer Service at the phone number listed on their member identification card to discuss their benefits more specifically. Providers with questions may call the Medica Provider Service Center toll-free at 1-800-458-5512.

Medica utilization management policies are not medical advice. Members should consult with appropriate health care providers to obtain needed medical advice, care, and treatment.

PURPOSE

To promote consistency between Utilization Management reviewers by providing the criteria that determine medical necessity.

BACKGROUND

I. Prevalence / Incidence

- A. It is reported that the lifetime incidence of low back pain (LBP) in the general population within the United States is between 60% and 90%, with an annual incidence of 5%. According to a National Center for Health Statistics study (Patel, 2007), 14.3% of new patient visits to primary care physicians per year are for LBP. Also, approximately 13 million physician visits are related to complaints of chronic LBP.
- B. More than 300,000 spinal fusion surgeries are performed annually in the United States. Degenerative disease is the most common reason for fusion surgery, with fusion often performed along with other spinal surgical procedures (e.g., disc decompression, decompression laminectomy). There are many variations on how spinal fusion is achieved, including different surgical approaches and techniques, and use of instrumentation or other available materials.

II. Definitions

- A. **Anterior lumbar spine surgery** is performed by the surgeon approaching the spine from the front of the body. The surgical site can be approached by a traditional front midline incision (i.e., through the abdominal musculature and retroperitoneal cavity) or by lateral approaches from the front side of the body (e.g., eXtreme lateral interbody fusion [XLIF]; direct interbody fusion [DLIF]; oblique interbody fusion [OLIF]). The surgical site can be accessed by open incision approaches or through percutaneous routes using image guidance. Anterior surgeries for correction of lumbar disc disease include discectomy, corpectomy, fusion, and bone grafting.
- B. **Artificial lumbar intervertebral disc replacement (arthroplasty)** is a surgical procedure in which a diseased or damaged intervertebral disc is replaced with an artificial device in individuals with symptomatic degenerative disc disease or herniated disc. They are intended to preserve/restore vertebral alignment, maintain spinal stability and flexibility, and alleviate pain. Surgery is performed in-patient and requires general anesthesia.
- C. **Artificial lumbar intervertebral discs** that have received U.S. Food and Drug Administration (FDA) approval include:
 - i. Inmotion® Lumbar Artificial Disc system (formerly Charite™ Artificial Disc)
 - ii. activL® Artificial Disc system

iii. PRODISC®-L Total Disc Replacement system.

- D. **Cauda equina syndrome (CES)** is a rare disorder characterized by impairment of the bundle of spinal nerve roots arising from the cauda equine (i.e. lumbar plexus) at the lower end of the spinal cord. CES may or may not be painful, but may result in numbness or tingling in the buttocks, perineum, genitalia and legs. Predominant symptoms include acute, rapidly progressive loss of bowel or bladder control or acute, sudden weakness and/or numbness in the leg (e.g., sudden foot drop/claudeication and/or inability to stand). Cauda equina is usually a surgical emergency requiring immediate hospitalization.
- E. **Chronic discogenic pain** is severe, recurring or constant pain originating from the intervertebral disc that limits the individual's ability to function. The term is most frequently used when the patient has relatively mild pathology on imaging studies, and does not have significant spondylosis, instability, radicular or myelopathic findings. Surgery is rarely indicated to treat this condition.
- F. **Corpectomy/hemicorpectomy** is removal of the entire vertebral body and removal of surrounding discs to relieve nerve and/or spinal cord impingement. When the pathology dictates that only a portion of the vertebral body be removed, the procedure is referred to as a *hemicorpectomy*.
- G. **Decompression surgery** is a general term that refers to various procedures intended to relieve symptoms caused by pressure, or compression, on the spinal cord and/or nerve roots. Bulging or collapsed disks, thickened joints, enlarged ligaments and bony growths can narrow the spinal canal and the spinal nerve openings (foramen), causing irritation. Examples of procedures include discectomy; laminotomy/laminectomy; foraminotomy; osteophytectomy (i.e., bone spur removal); and corpectomy.
- H. **Degenerative disc disease (DDD)** is a general term indicating a progressive drying out and degeneration of the intervertebral disc that leads to loss of spine flexibility and function. DDD is part of the normal aging process and develops over time. It can cause neck pain and stiffness.
- I. **Discectomy** is the surgical removal of the intervertebral disc. It can refer to removing the entire disc, as in an anterior discectomy and fusion, or simply a herniated portion of the nucleus pulposus (the central portion of the intervertebral disc), which is pressing on a nerve root or the spinal cord. Infrequently (i.e., 5% – 10% of discectomies), additional nuclear material may extrude through the same annular defect at any time after the primary discectomy surgery. This condition is termed "recurrent disc herniation."
- J. **Facet joints** are small joints that are located on the back of the spine, one on each side. Each vertebra is connected by facet joints. They provide stability to the spine by interlocking two vertebrae.
- K. **Facetectomy** is spine surgery to partially remove one or both of the facet joints on a set of vertebrae in the spine. A lumbar facetectomy is intended to remove the pressure of the spinal nerve roots near the facet joint when conservative medical treatment fails.
- L. The **lamina** is the flat area of bone between the superior process of the facet joint and the spinous process. The lamina is located on either side of the spinous process and forms the back of the central canal through which the spinal cord passes.
- M. **Laminectomy** is a surgical procedure performed to remove the lamina. It is also referred to as decompression surgery. A laminectomy enlarges the spinal canal and is intended to relieve pressure on the spinal cord and surrounding nerves.
- N. **Laminoplasty** is also performed to relieve pressure on the spinal cord and nerve roots. However, instead of removing the lamina, the lamina is partially cut on one side, creating a hinge, and completely cut on the other side. The lamina is then opened and held in place with the use of small bone plates and screws. An alternative method creates hinges on both side of the lamina and opens similar to a French-style door.
- O. **Laminotomy (hemilaminectomy; laminoforaminotomy)** is a surgical transection of vertebral lamina performed to decompress a nerve. It consists of partially removing a portion of the lamina overlying the compressed nerve to access and remove a disc herniation or to remove osteophytes. The procedure can be done on one or both sides of the spinous process.
- P. **Oswestry Disability Index (ODI)** is a standard self-administered, low back pain disability questionnaire used by clinicians and researchers to measure a patient's functional disability at a certain point in time.
- Q. **OsteoAmp™ allogenic morphogenic protein** is marketed for use for orthopedic indications. OsteoAMP is comprised of allogeneic bone (i.e., cadaver-derived) with BMP-2, BMP-7 and other endogenous growth factors derived from the allogeneic bone marrow. These other growth factors are

additional proteins with osteoinductive, angiogenic, and mitogenic properties and are bound to the bone during the harvesting process. OsteoAMP is available in various forms, including a compressible sponge, putty for mixing with bone marrow or blood, and granules for incorporation with mineralized allograft bone chips.

- R. **Post laminectomy syndrome**, also known as **failed lumbar surgery syndrome; failed back surgery syndrome (FBSS)**, is characterized by persistent back and/or leg pain following otherwise successful back surgery, frequently following a laminectomy. Following spine surgery, major pain relief is expected, but rarely is there total pain relief. A fraction of post-surgical pain is normal. However, the term post laminectomy syndrome or FBSS is reserved for individuals who continue to suffer from a majority of their pain symptoms following surgery.
- S. **Posterior lumbar spine surgery** is performed by the surgeon approaching the spine through the individual's back. The surgical site can be approached by a traditional back midline incision or transforaminally through the opening between two spinal vertebrae (i.e. the foramen) where the nerves leave the spinal canal to enter the body (e.g., transforaminal lumbar interbody fusion [TLIF], posterior lumbar interbody fusion [PLIF]). The surgical site can be accessed by open incision approaches or through percutaneous routes using image guidance. Posterior surgeries for correction of lumbar disc disease include discectomy, corpectomy, foraminectomy/ foraminotomy, laminectomy/laminotomy, fusion, and bone grafting.
- T. **Pseudarthrosis** (aka "false joint") is a term that is used to describe the situation where the spinal segment does not grow together (i.e., non-union) after an attempted surgical fusion. Symptoms normally present as post-operative axial (neck or back) or radicular (arms or leg) pain. Surgery to correct a pseudarthrosis is considered a repeat/revision fusion.
- U. **Radiculopathy** refers to a loss of sensory, motor, or reflex function or pain in a specific region as a result of irritation and/or compression of a spinal nerve root. Radiculopathy often presents clinically as pain traveling down the leg or arm, often accompanied by numbness and/or weakness in the limb.
- V. **Recombinant human bone morphogenic protein-2 (rhBMP-2)** is FDA-approved and available for use in the United States. BMPs are proteins naturally found in the body and many types (i.e., 2, 4, 6, 7, 9) assist with bone formation. Unlike standard bone allografts and autografts, BMP-2 is synthetically manufactured by using a technique called recombinant technology. BMP-2 is the active agent in the complete system. The system is comprised of recombinant human bone morphogenic protein-2, which is applied to an absorbable collagen sponge and inserted into an interbody support cage (e.g., titanium LT-CAGE™) prior to placement between the affected discs. The interbody LT-CAGE™ (Medtronic) is most commonly used to support the rhBMP-2, but other interbody cages are also available for use.
- W. **Scoliosis** (from the Greek word *skoliōsis*, meaning "crooked condition") is a complex three-dimensional deformity in which the spine is curved laterally (i.e., from side to side) and twisted rotationally. Large curves can cause postural imbalance which lead to muscle fatigue and pain. With advanced curvature, scoliosis can interfere with breathing, cause nerve or spinal cord compression, and lead to arthritis of the spine (spondylosis). Most scoliosis is idiopathic with onset in adolescence, but in rare cases scoliosis can be congenital and present at birth or result from neurological conditions such as cerebral palsy or myelodysplasia.
- X. **Skeletal (bone) maturity** occurs when bone growth ceases after puberty and refers to demonstration of fusion of growth plates (i.e., epiphyses and apophyses). Females reach skeletal maturity at approximately 16 years of age, while males reach skeletal maturity around 18 years of age. Radiographs of the hand and wrist with subsequent mathematical calculations are often used when exact measurement of skeletal maturity is warranted.
- Y. **Spinal fusion** (also known as spinal arthrodesis) is a procedure that permanently causes two or more vertebrae to grow together. A bone graft (autograft, allograft, or synthetic graft) is placed between the vertebrae or facet joints to stimulate the growth of bone across the joint, with the intent of improving stability, decreasing pain, or correcting deformity.
- Z. **Spinal instability** refers to loss of motion segment integrity which results in excessive motion within a spinal segment that could result in neurological deficit, deformity, or pain. Instability can be categorized as acute (e.g., spine fractures, spinal dislocations) or chronic (i.e., caused by degeneration of the joint through the normal aging process or diseases such as rheumatoid arthritis). Instability can be clinically simulated when movement of the painful spine segment produces abnormally excessive motion (e.g., flexion, extension, lateral angulation, translation) compared to the movement of a non-affected segment. Instability can also be demonstrated on

radiographic images by seeing excessive angulation or malalignment of spinal segments (e.g., spinout processes, facet joints, or vertebral bodies. Conditions or diseases associated with spinal instability include, but are not limited to, trauma, tumors, infections, connective tissue disorders, congenital disorders, degenerative disorders, and postsurgical events.

- AA. **Spinal instrumentation** refers to devices that surgeons implant in the spine during spinal surgery, often made of titanium, titanium-alloy, stainless steel, or plastic. These implants are available in many shapes and sizes and include rods, hooks, braided cable, plates, screws, and interbody prostheses and devices.
- BB. **Spinal stenosis** is a reduction in the diameter of the spinal canal caused by bone spur formation, disc herniation, hypertrophic (thickened) ligaments, or traumatic displacement of bone or soft tissue. Some individuals are born with small or stenotic spinal canals. Stenosis often results in pressure on the spinal cord and/or nerve root compression leading to significant pain and nerve-related symptoms or paralysis.
- CC. **Spondylolisthesis** can occur when one vertebra slips forward and out of alignment with the vertebra lying below it. It is commonly seen in the fourth over the fifth lumbar vertebra or the fifth over the sacrum. The causes can be congenital, due to stress fractures, facet degeneration, injury, or after decompression surgery. The condition may be asymptomatic, or cause significant pain and nerve-related symptoms. If the slippage occurs backwards, it is referred to as **retrolisthesis** and lateral slippage is called **lateral listhesis**.
- DD. **Synthetic ceramic-based and bioactive glass bone substitutes/fillers** are synthetically produced bone substitutes/extenders and void fillers used to fill voids and gaps in bone structure including the spine. These products can be obtained as injectables, pastes, solid matrices, and granules. Ceramic-based bone grafts are made up of collagen, calcium phosphate (CaP), calcium sulfate and one or more of the following products: Synthetic hydroxyapatite (HA), beta-tricalcium phosphates (B-TCP), biphasic calcium phosphate (BCP) (consists of both HA and β -TCP), and bioactive glass. These products have been proposed for use as stand-alone products or in combination with other bone substitutes and/or enhancement products.
- EE. **Tethered spinal cord syndrome** is a stretch-induced condition that results in fixation (tethering) of inelastic tissue to the lower spine, usually in the caudal spinal region (e.g., the filum terminale). This results in limited movement. Symptoms usually begin in infancy or childhood, and progress as a child ages when increased tension is applied to the spine. Progression of neurological signs and symptoms are highly variable, and some individuals do not experience noticeable symptoms until adulthood. Tethered spinal syndrome can be reversible if surgically treated (e.g., laminectomy and cord release) in its early stages.
- FF. **Tobacco/Nicotine products** can result in nicotine addiction and health problems, including a negative effect on bone and tissue healing. This includes delayed unions, nonunions and other complications (e.g., decreased blood flow to the discs; wound complications). Products containing nicotine include, but are not limited to, (1) smoked tobacco (e.g., cigarettes, cigars, cigarillos, kreteks, pipe tobacco), (2) smokeless tobacco (e.g., chewing tobacco, snuff), (3) electronic cigarettes (E-cigarettes), (4) nicotine vaping, (5) dissolvable tobacco, and (6) nicotine patches. Nicotine or its primary metabolite, cotinine, is most often tested to evaluate use. Both can be measured qualitatively or quantitatively for determination of (1) active use, (2) users who have recently quit, or (3) exposure in non-tobacco/nicotine users. Urine or blood testing is most commonly performed, although cotinine can also be measured in saliva.

III. Medical Management

- A. Individuals presenting with mild to moderate low back pain (LBP) arising from numerous etiologies are often treated with conservative medical management. Measures commonly used include:
- i. Behavior modification (e.g., smoking cessation, weight reduction)
 - ii. Cessation/modification of any identifiable inciting activity (e.g., sports injury)
 - iii. Epidural or facet injection therapy
 - iv. Lumbar bracing
 - v. Medication (e.g., analgesics, anti-inflammatories, muscle relaxants, tricyclic antidepressants, anti-epileptics)
 - vi. Physical therapy regimen (e.g., exercise, manual manipulation therapy)
 - vii. Chiropractic care
 - viii. Transcutaneous electrical stimulation.
- B. Conservative management is not recommended when there is evidence of:

- i. Infectious condition of the spine
- ii. Significant or progressive neurological deficit
- iii. Progressive spinal deformity
- iv. Some degree of traumatic injury
- v. Unstable fracture or dislocation
- vi. Acute cauda equina.

BENEFIT CONSIDERATIONS

1. Prior authorization **is required** for non-emergent lumbar spinal surgery or combination surgery.
2. Beginning with January 01, 2023 dates of service for **Medica Medicare members only**, prior authorization **is required** for intraoperative neurophysiologic monitoring performed at the time of lumbar spine surgery. See Medica's Utilization Management Policy, *Intraoperative Neurophysiologic Monitoring (IONM)*.
3. Refer to Medica's Utilization Management Policy, *Sacroiliac Joint Fusion, Open and Minimally Invasive*, for medical necessity criteria for sacroiliac joint fusion.
4. Prior authorization is **not required** for tethered spinal cord syndrome in infants, children, and adults.
5. Prior authorization is **not required** for the type of access and associated instrumentation used to gain entry to the surgical site, including:
 - a. Anterior access. Anterior access for lumbar fusion is referred to as anterior lumbar interbody fusion (ALIF) access.
 - b. Lateral access. Lateral access for lumbar fusion is referred to as lateral LIF (LLIF) access.
 - c. Posterior LIF (PLIF) access. Posterior access for lumbar fusion is referred to as posterior LIF (PLIF) access.
 - d. Transforaminal access. Transforaminal access for lumbar fusion is referred to as transforaminal LIF (TLIF) access.

Note: Exceptions are: (1) laparoscopic anterior lumbar interbody fusion (lap-ALIF) and (2) axial presacral lumbar interbody fusion (AxiaLIF®). These techniques have been determined to be investigative and therefore not covered.

6. Standard spinal instrumentation and/or tissue grafting materials are considered a covered benefit when all of the medical necessity criteria listed above are met, and not otherwise excluded according to terms in # 7, below.
7. Lumbar Intervertebral artificial disc replacement (arthroplasty) is investigative and therefore not covered for all other indications not listed above, including but not limited to treatment at more than one contiguous level and at disc levels not FDA-approved for the device being used.
8. If medical necessity criteria are not met as defined in this policy, any associated procedures (e.g., instrumentation, device implantation) will not be covered. This includes, but is not limited to, facility and anesthesia services, professional fees, and associated supplies.
9. Lumbar spinal surgery otherwise meeting medical necessity criteria defined in this policy is not covered when performed in combination with any procedure Medica considers investigative and therefore not covered.
10. Examples of procedures considered *investigative and therefore not covered* include, but are not limited to: autologous blood-derived products; stem cell and cellular bone matrix products for orthopedic applications; OsteoAmp™ allogenic morphogenic protein, synthetic ceramic-based and bioactive glass bone substitutes/fillers, i-Factor™ bone graft, motion preserving decompression/dynamic spine stabilization; axial presacral lumbar interbody fusion (AxiaLIF®); laparoscopic anterior lumbar interbody fusion (lap-ALIF); interspinous process decompression procedures; laser spine surgery; interosseous ablation of the basivertebral nerve; and selected percutaneous and minimally invasive lumbar spine procedures. See the following Medica coverage policies:
 - a. *Autologous Blood-Derived Products (Platelet-Rich Plasma, Autologous Conditioned Serum, Autologous Whole Blood)*.
 - b. *Stem Cell and Cellular Bone Matrix Products for Orthopedic Applications* (i.e., concentrated, engineered or expanded stem cells, as well as allograft bone products containing stem cells).
 - c. *Recombinant Human Bone Morphogenic Protein-2 (rhBMP-2) and Allogeneic Morphogenic Protein* (e.g., OsteoAMP™). NOTE: Some rhBMP-2 indications are covered services and others are non-covered services. Refer to coverage policy for details.
 - d. *Synthetic Ceramic-Based and Bioactive Glass Bone Substitutes/Fillers*.
 - e. *Motion Preserving Posterior Interspinous/Interlaminar Decompression/Stabilization Devices* (e.g., X-Stop, Coflex, Dynesys, DIAM spinal stabilization, Wallis system, total facet joint replacement

- system).
- f. *mild® Procedure (mild® Device Kit).*
 - g. *Laser Spine Surgery.*
 - h. *Intraosseous Ablation of Basivertebral Nerve for Treating Low-Back Pain (e.g., Intracept®).*
 - i. *Percutaneous Disc Decompression Procedures (Manual, Automated or Laser Discectomy, and Plasma Disc Decompression [PDD]).*
- 11. See related utilization management policy, *Facet Injections and Percutaneous Denervation Procedures (Radiofrequency and Laser Ablation) for Facet-Mediated Joint Pain (III-SUR.45).*
 - 12. Coverage may vary according to the terms of the member's plan document.
 - 13. If the Medical Necessity Criteria and Benefit Considerations are met, Medica will authorize benefits within the limits in the member's plan document.
 - 14. If it appears that the Medical Necessity Criteria and Benefit Considerations are not met, the case will be reviewed by the medical director or an external reviewer for individual consideration. Practitioners are advised of the appeal process in their Medica Provider Administrative Manual.

MEDICAL NECESSITY CRITERIA

Refer to the section below which corresponds with the surgical procedure(s), *initial or repeat/revision*, being requested:

- Section I: Emergent surgical need
- Section II: Lumbar decompression , stand-alone procedure
NOTE: If fusion is also request, use appropriate sections III-VII, below.
- Section III: Lumbar fusion, standard
- Section IV: Lumbar fusion, post laminectomy syndrome
- Section V: Lumbar fusion using InFUSE™ Bone Graft (i.e., recombinant human bone morphogenic protein-2 (rhBMP-2))
- Section VI: Lumbar intervertebral artificial disc replacement (arthroplasty)
- Section VII: Lumber fusion, chronic discogenic pain alone.

NOTE: Beginning with January 01, 2023 dates of service for **Medica Medicare members only**, prior authorization **is required** for intraoperative neurophysiologic monitoring performed at the time of lumbar spine surgery. See Medica's Utilization Management Policy, *Intraoperative Neurophysiologic Monitoring (IONM)*.

- I. Prior Authorization **is not required** when the procedure is **emergent in nature**. These indications include, but are not limited to:
 - A. Acute cauda equina syndrome (i.e., damage to the cauda equina causing loss of function in the lumbar plexus)
 - B. Acute, unremitting radicular pain resulting in severe rapid-onset/progression of neurological impairment arising from lumbar compression, nerve root compression, or stenosis and requiring emergent hospitalization within a few days post-onset/progression
 - C. Idiopathic scoliosis over 40 degrees of curvature
 - D. Congenital scoliosis
 - E. Infection-related instability, nerve or spinal cord compression, vertebral destruction, instability, or pathologic fracture
 - F. Acute, traumatic spinal fracture or dislocation with neural compression and/or radiographic evidence of instability
 - G. Spinal tuberculosis
 - H. Tumor-related (benign or malignant) nerve or spinal cord compression, vertebral destruction, instability, or pathologic fracture.
- II. Prior authorization **is required** for **initial and repeat/revision lumbar decompression** as a *stand-alone procedure*.
NOTE: If lumbar decompression is being done in combination with lumbar fusion, medical necessity criteria for lumbar fusion apply. Refer to appropriate fusion criteria sections III-VII, below.
Lumbar decompression alone is considered medically necessary when **all of the following** criteria are met:
 - A. Individual is undergoing **one of the following** procedures:
 - 1. Discectomy
 - 2. Corpectomy

3. Hemisectomy
4. Facetectomy
5. Foraminectomy/foraminoplasty
6. Foraminotomy
7. Laminectomy
8. Laminoplasty
9. Laminotomy (i.e., laminoforaminotomy, hemilaminectomy)
10. Osteophylectomy (i.e., bone spur removal).

B. Individual has **one of the following** documented diagnoses, exclusive of those listed in I., above:

1. Chronic radiculopathy with nerve root compression
2. Spondylolisthesis, anterolisthesis, or retrolisthesis
3. Symptomatic lumbar stenosis (e.g., pain, motor weakness, paresthesia, compromised neurological function)
4. Post laminectomy syndrome
5. Disc herniation, initial or recurrent (i.e., remaining disc material following initial lumbar discectomy).

C. Decompression surgery is not to exceed two lumbar levels.

An example of three lumbar levels would be L2-L3 & L3-L4 & L4-L5. See Appendix 1, below.

NOTE: If lumbar decompression is being requested at more than two levels, a medical director will review for medical necessity.

D. Skeletal maturity has been reached.

E. Documentation of **all of the following** criteria related to current episode and symptoms are met:

1. Documentation of continued episodes of severe, radiating neurological pain and/or impairment (e.g., extremity weakness, foot drop, numbness and/or decreased sensation, bladder and/or bowel dysfunction) demonstrating compromised ability to perform routine activities of daily living (e.g., standing, walking, climbing steps, bathing/grooming, food preparation).
2. Imaging studies/radiographic imaging (computed tomography; magnetic resonance imaging) documents spinal lesion(s) at a level correlating with clinical presentations mentioned in E.1. above.
3. Individual meets **one of the following**:
 - a. Completion of three months conservative management, including physical therapy or spinal manipulation by a chiropractor, and documentation of **one of the following**:
 - i. Less than 30% improvement in Oswestry Disability Index (ODI) score between first and last conservative treatment session
 - ii. Continued ODI score of greater than or equal to 30% at the conclusion of conservative treatment and thereafter.
 - b. For individuals who have not attempted or are unable to complete a minimum of three months conservative management, including physical therapy or spinal manipulation, documentation of a continued ODI score of greater or equal to 30% and documentation of **one of the following**:
 - i. Assessment by the individual's physical therapist or spine surgeon stating the clinical reasons why conservative management is contraindicated
 - ii. Assessment by the individual's physical therapist stating the clinical reasons (e.g., causes of progressive debilitating pain and/or disability) why physical therapy was not able to be complete.
 - c. Neurologic impairment (e.g., weakness on physical examination; bowel or bladder dysfunction).

NOTE: An ODI questionnaire with scoring/interpretation directions is found in Appendix 3, below.

III. Prior Authorization **is required** for **initial and repeat/revision lumbar fusion**, *with or without accompanying decompression*. Surgery is considered medically necessary when **all of the following** criteria are met:

NOTE: If lumbar fusion is being done for any of the following, refer to appropriate criteria sections, below:

- Section IV: fusion for post laminectomy syndrome (aka, failed back surgery syndrome)
- Section V: fusion in combination with recombinant human bone morphogenic protein-2 (rhBMP-2)
- Section VI: Lumbar intervertebral artificial disc replacement (arthroplasty)

- Section VII: fusion for chronic discogenic pain, *alone* (i.e., none of the following present: confirmed instability, deformity, or nerve root decompression at the surgical level).
- A. Individual has **one of the following** documented diagnoses, exclusive of those listed in I., above.
1. Spondylolisthesis, anterolisthesis, or retrolisthesis
 2. Non-acute radiculopathy (e.g., symptomatic lumbar stenosis, segmental scoliosis, osteophytes) causing continued pain, motor weakness, paresthesia, and/or compromised neurological function indicative of nerve root compression
 3. Post laminectomy syndrome
 4. Recurrent disc herniation (i.e., remaining disc material following initial lumbar discectomy).
- B. Skeletal maturity has been reached.
- C. Surgery is not to exceed two lumbar levels. An example of three lumbar levels would be L2-L3 & L3-L4 & L4-L5. See Appendix 1, below.
- NOTE: If either fusion or decompression is requested for more than two levels, send for medical director review for medical necessity.
- D. If osteoporosis is identified in medical history or imaging, documentation of osteoporosis status demonstrates one of the following:
1. Significant anatomical and/or neurological compromise necessitating surgical intervention despite presence of osteoporosis
 2. Bone structure has ability to support instrumentation.
- E. BMI less than 40 at the time of the prior authorization request.
- F. Documentation of continued episodes of severe, radiating neurological pain and/or impairment (e.g., extremity weakness, foot drop, numbness and/or decreased sensation, bladder and/or bowel dysfunction) demonstrating compromised ability to perform routine activities of daily living (e.g., standing, walking, climbing steps, bathing/grooming, food preparation).
- G. Imaging studies/radiological evidence (computed tomography; magnetic resonance imaging) documents demonstrating lesion(s) at a level correlating with clinical presentations mentioned in F., above (e.g., damage/compromise to facet joint, spinous process, transverse process, disk, ligaments, and/or muscles).
- H. Documentation of **one of the following** related to current episode and symptoms:
1. Completion of three months conservative management, including physical therapy or spinal manipulation by a chiropractor, and documentation of **one of the following**:
 - a. Less than 30% improvement in ODI score between first and last conservative treatment session
 - b. Continued ODI score of greater than or equal to 30% at the conclusion of conservative treatment and thereafter.
 2. For individuals who have not attempted or are unable to complete a minimum of three months conservative management, including physical therapy or spinal manipulation, documentation of a continued ODI score of greater or equal to 30% and documentation of **one of the following**:
 - a. Assessment by the individual's physical therapist or spine surgeon stating the clinical reasons why conservative management is contraindicated
 - b. Assessment by the individual's physical therapist stating the clinical reasons (e.g., causes of progressive debilitating pain and/or disability) why physical therapy was not able to be complete.
 3. Neurologic impairment (e.g., weakness on physical examination; bowel or bladder dysfunction).
- NOTE: An ODI questionnaire with scoring/interpretation directions is found in Appendix 3, below.
- I. Documentation of tobacco or nicotine status indicating **one of the following**:
1. The individual is a non-tobacco or non-nicotine user
 2. The individual has been tobacco and nicotine free for **a minimum of one month** prior to the date of the prior authorization request.
- J. Documentation indicates an FDA approved bone graft or fusion material is being used, as applicable.
- NOTE: Certain materials (e.g., blood-derived biologics) are not subject to standard FDA approval.
- NOTE: If use of recombinant human bone morphogenic protein-2 (rhBMP-2) is indicated, use section V, below.

NOTE: Medica considers any of the following to be standard graft material following FDA approved indications, if applicable: (1) autograft (i.e., bone from individual) or cadaver-derived bone allograft or (2) demineralized bone matrices (DBMs). See Appendix 4, Demineralized Bone Matrix (DBM) Products, following, for available DBMs and FDA approved uses.

NOTE: Medica considers (1) autologous blood-derive biologics (e.g., platelet-rich plasma, autologous conditioned serum, autologous whole blood), (2) stem cell and cellular bone matrix products (e.g. AlloStem®, Cellentra™ VCBM, Osteocel® Plus, Trinity® Evolution™), (3) OsteoAmp™ allogeneic morphogenic protein, and (4) synthetic ceramic-based and bioactive glass bone substitutes/fillers, and i-Factor bone graft *investigative and therefore not covered* for orthopedic applications.

- IV. Prior authorization is required for **initial and repeat/revision lumbar fusion for treatment of documented post laminectomy syndrome** (aka, failed back surgery syndrome). Surgery is considered medically necessary when **all of the following** criteria are met:

NOTE: If fusion level does not match that of the initial procedure, use section III, Lumbar fusion, standard.

- A. Individual meets criteria outlined in III.A.-J., above.
- B. Documentation of disability and unremitting pain for a minimum of three months following initial procedure.
- C. Documentation of preoperative psychiatric/psychological evaluation conducted within the past 12 months by a licensed psychologist or psychiatrist, or other licensed mental health professional who has an appropriate working knowledge of the psychosocial issues involved in management of chronic pain, including documentation of **all of the following**:
 - 1. Ability of the individual to understand the risks and goals of the surgical procedure
 - 2. Absence of unmanageable acute psychiatric illness and/or psychological distress, including but not limited to depression, drug abuse, or alcohol abuse
 - 3. Ability of the individual to understand the need to comply with long-term aftercare and with the behavioral changes expected after surgery.

- V. Prior authorization is required for **initial and repeat/revision lumbar fusion**, with or without accompanying decompression, **in combination with a recombinant human bone morphogenic protein-2 (rhBMP-2) system (i.e., InFUSE™ Bone Graft)** and is considered medically necessary when **all of the following** criteria are met:

- A. Individual meets criteria outlined in III.A.- J., above.
- B. Recombinant human bone morphogenic protein-2 (rhBMP-2; InFUSE rhBMP Bone Graft) is the bone graft component being employed.

NOTE: the interbody LT-CAGE™ (Medtronic) is most commonly used to support the rhBMP-2, but other interbody cages are also available for use.

NOTE: Medica considers OsteoAmp™ allogenic morphogenic protein *investigative and therefore not covered* for orthopedic applications.

- C. **Both of the following** FDA-approved InFUSE rhBMP-2 Bone Graft indications are met:
 - 1. Anterior-approach is documented.
 - 2. *Single level* application is documented for insertion from the fourth lumbar vertebra to the first sacral vertebra (L4-S1).

- VI. Prior authorization is required for **initial and repeat/revision lumbar intervertebral artificial disc replacement (arthroplasty)** . Surgery is considered medically necessary when **all of the following** criteria are met:

- A. Individual has documented symptomatic degenerative disc disease (DDD), with or without radicular pain, resulting in unremitting low back pain, exclusive of those listed in I., above.

NOTE: Examples of associated underlying causes include, but are not limited to: (1) degenerative disc disease, (2) unstable spinal stenosis, (3) degenerative scoliosis, (4) segmental instability, (5) unstable failed back surgery syndrome (i.e., post-laminectomy syndrome), (6) unstable post-facetectomy syndrome.

- B. Documentation of continued episodes of unremitting back pain demonstrating compromised ability to perform routine activities of daily living (e.g., standing, walking, sitting, climbing steps, bathing/grooming, food preparation).
- C. Medical record does not indicate **any of the following**:
 - 1. Moderate to severe facet joint arthritis
 - 2. Localized or systemic infection.
 - 3. Spinal tumor or other active malignancy
 - 4. Osteoporosis
 - 5. Spondylolisthesis.

- D. Imaging studies/radiological evidence (computed tomography; magnetic resonance imaging) documents a DDD lesion at a level correlating with impaired ADLs as mentioned in B, above.
 - E. Skeletal maturity has been reached.
 - F. BMI is less than 40 at the time of the prior authorization request.
 - G. Documentation of insertion at one-level.
 - H. Procedure will be performed using an FDA-approved device for **one of the following**:
 - 1. From L4-S1 when using **one of the following**:
 - 1. Inmotion® Lumbar Artificial Disc system (formerly Charite™ Artificial Disc)
 - 2. activL® Artificial Disc system.
 - 2. From L3-S1 when using PRODISC®-L Total Disc Replacement system.
 - I. Documentation of **one of the following** related to current episode and symptoms:
 - 1. Completion of six months conservative management, including physical therapy or spinal manipulation by a chiropractor, and documentation of **one of the following**:
 - a. Less than 30% improvement in ODI score between first and last conservative treatment session
 - b. Continued ODI score of greater than or equal to 30% at the conclusion of conservative treatment and thereafter.
 - 2. For individuals who have not attempted or are unable to complete a minimum of six months conservative management, including physical therapy or spinal manipulation, documentation of a continued ODI score of greater than or equal to 30% and documentation of **one of the following**:
 - a. Assessment by the individual's physical therapist or spine surgeon stating the clinical reasons why conservative management is contraindicated
 - b. Assessment by the individual's physical therapist stating the clinical reasons (e.g., causes of progressive debilitating pain and/or disability) why physical therapy was not able to be complete.
 - 3. Neurologic impairment (e.g., weakness on physical examination; bowel or bladder dysfunction).
- NOTE: An ODI questionnaire with scoring/interpretation directions is found in Appendix 3, below.

VII. Prior authorization **is required for initial and repeat/revision lumbar fusion when ordered for chronic discogenic pain, alone**. Surgery is considered medically necessary when **all of the following** criteria are met:

- A. Skeletal maturity has been reached.
- B. Continued discogenic pain has persisted for a minimum of **six months**.
- C. Spinal instability, deformity, and/or nerve root decompression is not present, as documented by **one of the following**:
 - 1. Imaging studies
 - 2. Physical examination (e.g., segmental instability testing).
- D. Surgery is not to exceed two lumbar levels. An example of three lumbar levels would be L2-L3 & L3-L4 & L4-L5. See Appendix 1, below.

NOTE: If lumbar fusion is being requested at more than two levels, send -to medical director for medical necessity review.
- E. BMI less than 40 at time of the prior authorization request.
- F. Documentation of preoperative psychiatric/psychological evaluation conducted within the past 12 months by a licensed psychologist or psychiatrist, or other licensed mental health professional who has an appropriate working knowledge of the psychosocial issues involved in management of chronic pain, including documentation of **all of the following**:
 - 1. Ability of the individual to understand the risks and goals of the surgical procedure
 - 2. Absence of unmanageable acute psychiatric illness and/or psychological distress, including but not limited to depression, drug abuse, or alcohol abuse
 - 3. Ability of the individual to understand the need to comply with long-term aftercare and with the behavioral changes expected after surgery.
- G. Failures of **all of the following**:
 - 1. Minimum of six months **intensive** medical management, including active, organized and progressive physical therapy program addressing strength and flexibility)
 - 2. Anti-inflammatory medication and/or analgesics
 - 3. Regimen of therapeutic injections.
- H. Documentation, within one month prior to surgery, of the Oswestry Disability Index (ODI) scores demonstrating **one of the following**:

1. Less than 30% improvement in ODI score between first and last conservative treatment session.
2. Continued ODI score of greater than or equal to 40% at the conclusion of conservative treatment and thereafter.

NOTE: An ODI questionnaire with scoring/interpretation directions is found in Appendix 3, below.

- I. Documentation of tobacco or nicotine status indicating **one of the following**:
 1. The individual is a non-tobacco or non-nicotine user
 2. The individual has been tobacco and nicotine free for a **minimum of six months** prior to the date of the prior authorization request.
- J. Documentation indicates an FDA approved bone graft or fusion material is being used, as applicable.

NOTE: Certain materials (e.g., blood-derived biologics) are not subject to standard FDA approval.

NOTE: If use of human bone morphogenic protein-2 (rhBMP-2) is indicated, use section V., above.

NOTE: Medica considers **any of the following** to be standard graft material following FDA approved indications, if applicable: (1) autograft (i.e., bone from individual) or cadaver-derived bone allograft or (2) demineralized bone matrices (DBMs) See Appendix 4, Demineralized Bone Matrix (DBM) Products, following, for available DBMs and FDA approved uses.

NOTE: Medica considers (1) autologous blood-derive biologics (e.g., platelet-rich plasma, autologous conditioned serum, autologous whole blood), (2) stem cell and Cellular Bone Matrix Products (e.g., AlloStem®, Cellentra™ VCBM, Osteocel® Plus, Trinity® Evolution™), (3) OsteoAMP™, (4) synthetic ceramic-based and bioactive glass bone substitutes/fillers allogeneic morphogenic protein, and (5) i-Factor bone graft **investigative and therefore not covered**.

CENTERS FOR MEDICARE & MEDICAID SERVICES (CMS)

- For Medicare members, refer to the following, as applicable at: <https://www.cms.gov/medicare-coverage-database/search.aspx>

MINNESOTA HEALTH CARE PROGRAMS (MHCP)

- For MHCP members, refer to https://www.dhs.state.mn.us/main/idcplg?IdcService=GET_DYNAMIC_CONVERSION&RevisionSelectionMethod=LatestReleased&dDocName=id_000094#
- No MHCP policy found as of 10/03/2023.

DOCUMENT HISTORY

Original Effective Date	December 1, 2010
MPC Endorsement Date(s)	09/2011, 09/2012, 06/2013, 09/2013, 11/2013, 11/2014, 11/2015, 11/2016, 11/2017, 11/2018, 11/2019, 11/2020, 11/2021, 11/2022, 11/2023
Administrative Updates	02/2017; 05/01/2017; 06/21/2018; 05/17/2021

References:

Pre-11/2014 Medical Policy Committee (MPC) and Pre-09/2015 Medical Technology Assessment Committee (MTAC):

1. Adogwa O, Parker SL, Shau D, et al. Long-term outcomes of revision fusion for lumbar pseudoarthrosis. *J Neurosurg Spine*. 2011;15:393-398.
2. Baaj AA, Downes K, Vaccaro AR, et al. Trends in the treatment of lumbar spine fractures in the United States: a socioeconomics perspective. *J Neurosurg Spine*. 2011;15:367-370.
3. Boswell MV, Trescot AM, Datta S, et al. Interventional techniques: evidence-based practice guidelines in the management of chronic spinal pain. *Pain Physician*. 2007;10:7-111.
4. Cheng JS, Lee MJ, Massicotte E, et al. Clinical guidelines and payer policies on fusion for the treatment of chronic low back pain. *Spine*. 2011;36(21S):S144-S163.
5. Chou R. Subacute and chronic low back pain: surgical treatment. In: Basow, DS (Ed). *UpToDate*. Waltham, MA: Up to Date; 2013.

6. Chou R, Baisden J, Carragee EJ, Resnick DK, Shaffer WO, Loeser JD. Surgery for low back pain: a review of the evidence for an American Pain Society Clinical Practice Guideline. *Spine*. 2009;34(10):1094-1109.
7. Chou R, Loeser JD, Owens DG, et al. Interventional therapies, surgery, and interdisciplinary rehabilitation for low back pain: an evidence-based clinical practice guideline from the American Pain Society. *Spine*. 2009;34:1066-1077.
8. Davidson M, Keating JL. A comparison of five low back disability questionnaires: reliability and responsiveness. *Phys Ther*. 2002;82:8-14.
9. Deyo RA, Mirza SK, Martin BI, et al. Trends, major medical complications, and charges associated with surgery for lumbar spinal stenosis in older adults. *JAMA*. 2010;303(13):1259-1310.
10. ECRI Institute. *Health Technology Assessment: Spinal Fusion and Discography for Chronic Low Back Pain and Uncomplicated Lumbar Degenerative Disc Disease (Washington HTA)*. October 2007. Plymouth Meeting PA.
11. ECRI Institute. *Hotline Response: Systematic Reviews, Cost-effectiveness, and Guidelines for Lumbar Spinal Fusion*. October 2011. Plymouth Meeting PA.
12. Fairbank JC, Pynsent PB. The Oswestry Disability Index. *Spine*. 2000;25(22):2940-2952.
13. Fischer CR, Kim Y. Selective fusion for adolescent idiopathic scoliosis: a review of current operative strategy. *Eur Spine J*. 2011;20:1048-1057.
14. Fritzell P, Berg S, Borgstrom, et al. Cost effectiveness of disc prosthesis versus lumbar fusion in patients with chronic low back pain: randomized controlled trial with 2-year follow-up. *Eur Spine J*. 2011;20:1001-1011.
15. Fosco M, Di Fiore M. Factors predicting blood transfusion in different surgical procedures for degenerative spine disease. *Eur Rev Med Pharmacol Sci*. 2012;16(13):1853-1888.
16. Gibson JNA, Waddell G. Surgery for degenerative lumbar spondylosis. *Cochrane Database of Systematic Reviews*. 2005, Issue 4. Art. No.: CD001352. DOI: 10.1002/14651858.DC001352.pub3.
17. Jutte PC, van Loenhout-Rooyackers JH. Routine surgery in addition to chemotherapy for treating spinal tuberculosis. *Cochrane Database of Systematic Reviews*. 2006, Issue 1. Art. No.: CD0045232. DOI: 10.1002/14651858.CD004532.pubw.
18. Kim S, Hedjri SM, Coyte PC, et al. Cost-utility of lumbar decompression with or without fusion for patients with symptomatic degenerative lumbar spondylolisthesis. *Spine J*. 2012;12:44-54.
19. Kovacs FM, Urrutia G, Alarcon JD. Surgery versus conservative treatment for symptomatic lumbar spinal stenosis. *Spine*. 2011;36(20):E1335-E1351.
20. Levin K. Lumbar spinal stenosis: treatment and prognosis. In: Basow, DS (Ed). *UpToDate*. Waltham, MA: *Up to Date*; 2013.
21. McClendon J Jr, Smith TR, Thompson SE, et al. The impact of body mass index on hospital stay and complications after spinal fusion. *Neurosurgery*. 2014;74(1):42-50.
22. O'Grady I, McCarthy C, Kaliaperumal C, Marks JC, Kaar G, O'Sullivan M. Are we justified in doing blood tests 'routinely' for all neurosurgical patients? *Ir Med J*. 2013;106(1):18-20.
23. Pakzaban P. *Spinal Instability and Spinal Fusion Surgery*. eMedicine from WebMD. <http://emedicine.medscape.com/article/1343720-overview>. Last updated June 2010. Accessed September 3, 2014.
24. Patel RK, Slipman CW. *Lumbar Degenerative Disc Disease*. eMedicine Physical Medicine and Rehabilitation. Topic 67. Omaha, NE. <http://emedicine.medscape.com/article/309767-overview>. Last updated August 2009. Accessed December 10, 2014.
25. Pumberger M, Chiu Y-L, Ma Y, et al. National in-hospital morbidity and mortality trends after lumbar fusion surgery between 1998 and 2008. *J Bone Joint Surg [Am]*. 2012;94(3):359-364.
26. Resnick DK, Choudhri TF, Dailey AT, et al. Guidelines for the performance of fusion procedures for degenerative disease of the lumbar spine. Part 7: intractable low-back pain without stenosis or spondylolisthesis. *J Neurosurg Spine*. June 2005;2(6):670-672.
27. Resnick DK, Choudhri TF, Dailey AT, et al. Guidelines for the performance of fusion procedures for degenerative disease of the lumbar spine. Part 1: introduction and methodology. *J Neurosurg Spine*. 2005;2(6):637-638.
28. Resnick DK, Choudhri TF, Dailey AT, et al. Guidelines for the performance of fusion procedures for degenerative disease of the lumbar spine. Part 6: magnetic resonance imaging and discography for patient selection for lumbar fusion. *J Neurosurg Spine*. 2005;2(6):662-669.
29. Resnick DK, Choudhri TF, Dailey AT, et al. Guidelines for the performance of fusion procedures for degenerative disease of the lumbar spine. Part 8: lumbar fusion for disc herniation and radiculopathy. *J Neurosurg Spine*. 2005;2(6):673-678.
30. Resnick DK, Choudhri TF, Dailey AT, et al. Guidelines for the performance of fusion procedures for

- degenerative disease of the lumbar spine. Part 9: fusion in patients with stenosis and spondylolisthesis. *J Neurosurg Spine*. 2005;2(6):679-685.
31. Resnick DK, Choudhri TF, Dailey AT, et al. Guidelines for the performance of fusion procedures for degenerative disease of the lumbar spine. Part 10: fusion following decompression in patients with stenosis without spondylolisthesis. *J Neurosurg Spine*. June;2(6):686-691.
 32. Resnick DK. Evidence-based guidelines for the performance of lumbar fusion. *Clin Neurosurg*. 2006;53:279- 284.
 33. Sasaji T, Horaguchi K, Shinozaki N, Yamada N, Iwai Kazuo. Postoperative anemia following posterior decompression surgery for lumbar spinal canal stenosis. *Tohoku J Exp Med*. 2013;229:1-4.
 34. Schoenfeld AJ, Carey PA, Cleveland AW 3rd, Bader JO, Bono CM. Patient factors, comorbidities, and surgical characteristics that increase mortality and complication risk after spinal arthrodesis: a prognostic study based on 5,887 patients. *Spine J*. 2013;13(10):1171-1179.
 35. Seicean A, Siecian S, Alan N, et al. Pre-operative anemia and peri-operative outcomes in patients who undergo elective spine surgery. *Spine (Phila PA 1976)*. 2013;38(15):1331-1341.
 36. Slatis P, Malmivaara A, Heliövaara, et al. Long-term results of surgery for lumbar spinal stenosis: a randomized controlled trial. *Eur Spine J*. 2011;20:1174-1181.
 37. Stundner O, Taher F, Pawar A, Memtsoudis SG. Pulmonary complications after spine surgery. *World J Orthop*. 2012;3(10):156-161.
 38. Tso P, Waler K, Mahomed N, et al. Comparison of lifetime incremental cost: utility ratios of surgery relative to failed medical management for the treatment of hip, knee and spine osteoarthritis modeled using 2-year postsurgical values. *Can J Surg*. 2012;55(3):181-190.
 39. Vaidya R, Carp J, Bartol S, Ouellette N, Lee S, Sethi A. Lumbar spine fusion in obese and morbidly obese patients. *Spine (Phila Pa 1976)*. 2009;34(5):495-500.
 40. Vokshoor A. *Spondylolisthesis, Spondylolysis, and Spondylosis*. eMedicine from WebMD. <http://emedicine.medscape.com/article/1266860-overview>. Last updated June 2010. Accessed September 3, 2014.
 41. Walid MS, Zaytseva N, Porubaiko, et al. Recurrent spine surgery patients in hospital administrative database. *Ger Med Sci*. 2012;10:Doc03.
 42. Washington State Department of Labor and Industries. Office of the Medical Directory. *Medical Technology Guideline: Surgical Guideline for Lumbar Fusion (Arthrodesis)*. November 2009. Tumwater, WA.
 43. Watters WC, Bono CM, Gilber TJ, et al. An evidence-based clinical guideline for the diagnosis and treatment of degenerative lumbar spondylolisthesis. *Spine J*. 2009;9(7):809-814.
 44. Watters WC, Baisden J, Bono C, et al. *North American Spine Society Clinical Guidelines for Multidisciplinary Spine Care: Diagnosis and Treatment of Degenerative Lumbar Spondylolisthesis*. 2008. Burr Ridge IL.
 45. Watters WC, Baisden J, Gilbert T, et al. *North American Spine Society Clinical Guidelines for Multidisciplinary Spine Care: Diagnosis and Treatment of Degenerative Lumbar Spinal Stenosis*. 2007. Burr Ridge IL.
 46. Wheeler SG, Wipf JE, Staiger TO, Deyo RA. Approach to the diagnosis and evaluation of low back pain in adults. In: Basow, DS (Ed). *UpToDate*. Waltham, MA: Up to Date; 2013.

09/2015 MTAC:

47. Brinjikji W, Luetmer PH, Comstock B3, et al. Systematic literature review of imaging features of spinal degeneration in asymptomatic populations. *AJNR Am J Neuroradiol*. 2015;36(4):811-816. doi: 10.3174/ajnr.A4173.
48. Chou R. Subacute and chronic low back pain: Surgical treatment. Last updated March 16, 2015. In: *UpToDate*, Basow, DS (Ed), UpToDate, Waltham, MA, 2015.
49. Guyer RD, Pettine K, Roh JS, et al. Comparison of 2 lumbar total disc replacements: results of a prospective, randomized, controlled, multicenter Food and Drug Administration trial with 24-month follow-up. *Spine (Phila Pa 1976)*. 2014;39(12):925-931. doi: 10.1097/BRS.0000000000000319.
50. Hayes, Inc. *Hayes Directory: Lumbar Total Disc Replacement for Degenerative Disc Disease*. August 2015. Lansdale, PA.
51. Johnsen LG, Brinckmann P, Hellum C, Rossvoll I, Leivseth G. Segmental mobility, disc height and patient-reported outcomes after surgery for degenerative disc disease: a prospective randomised trial comparing disc replacement and multidisciplinary rehabilitation. *Bone Joint J*. 2013;95-B(1):81-89. doi: 10.1302/0301-620X.95B1.29829.
52. Oktenoglu T, Ozer AF, Sasani M, Ataker Y, Gomleksiz C, Celebi I. Posterior Transpedicular Dynamic

- Stabilization versus Total Disc Replacement in the Treatment of Lumbar Painful Degenerative Disc Disease: A Comparison of Clinical Results. *Adv Orthop*. 2013;2013:874090. doi: 10.1155/2013/874090.
53. Parkinson B, Goodall S, Thavaneswaran P. Cost-effectiveness of lumbar artificial intervertebral disc replacement: driven by the choice of comparator. *ANZ J Surg*. 2013;83(9):669-675. doi: 10.1111/ans.12009.
 54. Siepe CJ, Heider F, Wiechert K, Hitzl W, Ishak B, Mayer MH. Mid- to long-term results of total lumbar disc replacement: a prospective analysis with 5- to 10-year follow-up. *Spine J*. 2014;14(8):1417-1431. doi: 10.1016/j.spinee.2013.08.028.
 55. Sköld C, Tropp H, Berg S. Five-year follow-up of total disc replacement compared to fusion: a randomized controlled trial. *Eur Spine J*. 2013;22(10):2288-2295. doi: 10.1007/s00586-013-2926-y.
 56. Wei J, Song Y, Sun L, Lv C. Comparison of artificial total disc replacement versus fusion for lumbar degenerative disc disease: a meta-analysis of randomized controlled trials. *Int Orthop*. 2013;37(7):1315-1325. doi: 10.1007/s00264-013-1883-8.

11/2016 MPC and 04/2016 & 10/2016 MTAC:

57. Alqarni AM1, Schneiders AG, Hendrick PA. Clinical tests to diagnose lumbar segmental instability: a systematic review. *J Orthop Sports Phys Ther*. 2011;41(3):130-140. doi: 10.2519/jospt.2011.3457.
58. An H, Yeung C, Field J, Roh J. A radiographic analysis of posterolateral lumbar fusion utilizing an allogeneic growth factor compared to recombinant human bone morphogenetic protein-2 (rhBMP-2). *J Spine*. 2014;3(5).
59. Arce D1, Sass P, Abul-Khoudoud H. Recognizing spinal cord emergencies. *Am Fam Physician*. 2001;64(4):631- 638.
60. Bateman DK, Millhouse PW, Shahi N, et al. Anterior lumbar spine surgery: a systematic review and meta- analysis of associated complications. *Spine J*. 2015;15(5):1118-32. doi: 10.1016/j.spinee.2015.02.040.
61. Beazell JR, Mullins M, Grindstaff TL. Lumbar instability: an evolving and challenging concept. *J Man Manip Ther*. 2010;18(1):9-14. doi: 10.1179/106698110X12595770849443.
62. Buttermann GR, Mullin WJ. Two-Level Circumferential Lumbar Fusion Comparing Midline and Paraspinal Posterior Approach: 5-Year Interim Outcomes of a Randomized, Blinded, Prospective Study. *J Spinal Disord Tech*. 2015;28(9):E534-E543. doi: 10.1097/BSD.0000000000000029.
63. Buttner-Janzen K, Guyer RD, Ohnmeiss DD. Indications for lumbar total disc replacement: selecting the right patient with the right indication for the right total disc. *Int J Spine Surg*. 2014;8:12. doi: 10.14444/1012
64. Bydon M, De la Garza-Ramos R, Abt NB, et al. Impact of smoking on complication and pseudarthrosis rates after single- and 2-level posterolateral fusion of the lumbar spine. *Spine (Phila Pa 1976)*. 2014;39(21):1765-1770. doi: 10.1097/BRS.0000000000000527.
65. ECRI Institute. ECRI Product Brief: Infuse Bone Graft (Medtronic, Inc.) for Use in Lumbar Fusion and Tibia Repair Surgical Procedures. July 2014. Plymouth Meeting, PA.
66. ECRI Institute. ECRI Product Brief: OsteoAMP Bone Graft (Bioventus, LLC.) for Use in Spinal Fusion and Tibia Repair Procedures. June 2016. Plymouth Meeting, PA.
67. Elmasry S, Asfour S, de Rivero Vaccari JP, Travascio F. Effects of Tobacco Smoking on the Degeneration of the Intervertebral Disc: A Finite Element Study. *PLoS One*. 2015;10(8):e0136137. doi: 10.1371/journal.pone.0136137.
68. Field J, Yeun, C, Roh J. Clinical evaluation of allogeneic growth factor in cervical spine fusion. *J Spine*. 2014;3(2).
69. Försth P, Ólafsson G, Carlsson T, et al. A Randomized, Controlled Trial of Fusion Surgery for Lumbar Spinal Stenosis. *N Engl J Med*. 2016;374(15):1413-1423. doi: 10.1056/NEJMoa1513721.
70. Govil, A, Thompson, N. Osteoinductivity and osteogenicity of leading allograft bone products. *Orthopaedic Proceedings*. 2014.
71. Gulati S, Nordseth T, Nerland US, et al. Does daily tobacco smoking affect outcomes after microdecompression for degenerative central lumbar spinal stenosis? - A multicenter observational registry-based study. *Acta Neurochir (Wien)*. 2015;157(7):1157-1164. doi: 10.1007/s00701-015-2437-1.
72. Hayes Inc. Hayes Annual Review: Infuse Bone Graft (Medtronic, Inc.) for Use in Lumbar Fusion and Tibia Repair Surgical Procedures. July 2015. Lansdale, PA.
73. Hayes Inc. Hayes Directory: Recombinant Human Bone Morphogenetic Protein (rhBMP) for Use in Spinal Fusion. April 2014. Annual Review last updated March 2016. Lansdale, PA.
74. Hayes, Inc. Hayes Product Comparison: Demineralized Bone Matrix (DBM) - Spinal Products. September 2013. Lansdale, PA.
75. Hayes, Inc. Hayes Search & Summary: OsteoAMP (Bioventus) for Lumbar Fusion. March 2016. Lansdale, PA.

76. Hayes, Inc. Hayes Search & Summary: Arthroscopic Microdiscectomy for Lumbar Disc Herniation. September 2016. Lansdale, PA.
77. Nerland US, Jakola AS, Giannadakis C, et al. The Risk of Getting Worse: Predictors of Deterioration After Decompressive Surgery for Lumbar Spinal Stenosis: A Multicenter Observational Study. *World Neurosurg.* 2015;84(4):1095-1102. doi: 10.1016/j.wneu.2015.05.055.
78. Patel RA, Wilson RF, Patel PA, Palmer RM. The effect of smoking on bone healing: A systematic review. *Bone Joint Res.* 2013;2(6):102-111. doi: 10.1302/2046-3758.26.2000142.
79. Roh JS, Yeung CA, Field JS, McClellan RT. Allogeneic morphogenetic protein vs. recombinant human bone morphogenetic protein-2 in lumbar interbody fusion procedures: a radiographic and economic analysis. *J Orthop Surg Res.* 2013;849.
80. Saavedra-Pozo FM, Deusdara RA, Benzel EC. Adjacent segment disease perspective and review of the literature. *Ochsner J.* 2014;14(1):78-83.
81. Sayama C, Hadley C, Monaco GN, et al. The efficacy of routine use of recombinant human bone morphogenetic protein-2 in occipitocervical and atlantoaxial fusions of the pediatric spine: a minimum of 12 months' follow-up with computed tomography. *J Neurosurg Pediatr.* 2015;16(1):14-20. doi: 10.3171/2015.2.PEDS1453.
82. Sayama C, Willsey M, Chintagumpala M, et al. Routine use of recombinant human bone morphogenetic protein- 2 in posterior fusions of the pediatric spine and incidence of cancer. *J Neurosurg Pediatr.* 2015;16(1):4-13. doi: 10.3171/2014.10.PEDS14199.
83. Scheer JK, Dahdaleh NS, Smith ZA. Seroma observed 6 months after anterior lumbar interbody fusion that included use of recombinant bone morphogenetic protein 2. *Spine J.* 2015;15(10):e33. doi: 10.1016/j.spinee.2015.05.033.
84. Stensby JD, Kaliney RW, Alford B, Shen FH4, Patrie JT5, Fox MG1. Radiographic Appearance of Transforaminal Lumbar Interbody Fusion Performed With and Without Recombinant Human Morphogenetic Protein-2. *AJR Am J Roentgenol.* 2016;206(3):588-594. doi: 10.2214/AJR.15.14503.
85. Yeung C, Field J, and Roh J. Clinical validation of allogeneic morphogenetic protein: donor intervariability, terminal irradiation and age of product is not clinically relevant. *J Spine.* 2014;3(3).
86. Ying J, Huang K, Zhu M, et al. The Effect and Feasibility Study of Transforaminal Percutaneous Endoscopic Lumbar Discectomy Via Superior Border of Inferior Pedicle Approach for Down-Migrated Intracanal Disc Herniations. *Medicine (Baltimore).* 2016 Feb;95(8):e2899. doi: 10.1097/MD.0000000000002899.

11/2017 MPC:

87. Alentado VJ, Caldwell S, Gould HP, Steinmetz MP, Benzel EC, Mroz TE. Independent predictors of a clinically significant improvement after lumbar fusion surgery. *Spine J.* 2017 Feb;17(2):236-243. doi: 10.1016/j.spinee.2016.09.011.
88. Gaudin D, Krafcik BM, Mansour TR, Alnemari A. Considerations in Spinal Fusion Surgery for Chronic Lumbar Pain: Psychosocial Factors, Rating Scales, and Perioperative Patient Education-A Review of the Literature. *World Neurosurg.* 2017 Feb;98:21-27. doi: 10.1016/j.wneu.2016.10.124.
89. Ghogawala Z, Resnick DK, Glassman SD, Dziura J, Shaffrey CI, Mummaneni PV. Randomized controlled trials for degenerative lumbar spondylolisthesis: which patients benefit from lumbar fusion? *J Neurosurg Spine.* 2017 Feb;26(2):260-266. doi: 10.3171/2016.8.SPINE16716.
90. Machado GC, Ferreira PH, Yoo RI, et al. Surgical options for lumbar spinal stenosis. *Cochrane Database Syst Rev.* 2016 Nov 1;11:CD012421.
91. Xiaochuan L, Zhong CF, Tang JH, Liang RW, Luo SJ, Huang C2. The Effectiveness and Safety of Selective Lumbar Decompression in Diagnostic Doubt Patients: A Retrospective Control Study. *Pain Physician.* 2017 May;20(4):E541-E550.

11/2018 MPC:

92. Shehadi JA, Elzein SM. Review of commercially available demineralized bone matrix products for spinal fusions: A selection paradigm. *Surg Neurol Int.* 2017; 8: 203. doi: 10.4103/sni.sni_155_17.

11/2019 MPC:

93. Bai DY, Liang L, Zhang BB, et al. Total disc replacement versus fusion for lumbar degenerative diseases - a meta-analysis of randomized controlled trials. *Medicine (Baltimore).* 2019;98(29):e16460. doi: 10.1097/MD.00000000000016460.
94. Harris IA, Traeger A, Stanford R, Maher CG, Buchbinder R. Lumbar spine fusion: what is the evidence? *Intern Med J.* 2018;48(12):1430-1434. doi: 10.1111/imj.14120.

95. Kamson S, Lu D, Sampson PD, Zhang Y. Full-Endoscopic Lumbar Fusion Outcomes in Patients with Minimal Deformities: A Retrospective Study of Data Collected Between 2011 and 2015. *Pain Physician*. 2019;22(1):75-88.
96. Ma Z, Huang S, Sun J, Li F, Sun J, Pi G. Risk factors for upper adjacent segment degeneration after multi-level posterior lumbar spinal fusion surgery. *J Orthop Surg Res*. 2019;14(1):89. doi: 10.1186/s13018-019-1126-9.
97. Mu X, Wei J, A J, Li Z, Ou Y. The short-term efficacy and safety of artificial total disc replacement for selected patients with lumbar degenerative disc disease compared with anterior lumbar interbody fusion: A systematic review and meta-analysis. *PLoS One*. 2018;13(12):e0209660. doi: 10.1371/journal.pone.0209660.
98. Murphy ME, Mccutcheon BA, Grauberger J, et al. Allograft versus autograft in cervical and lumbar spinal fusions: an examination of operative time, length of stay, surgical site infection, and blood transfusions. *J Neurosurg Sci*. 2019;63(1):11-18. doi: 10.23736/S0390-5616.16.03847-9.

11/2020 MPC:

No new references.

11/2021 MPC:

99. Bortz C, Pierce KE, Alas H, et al. The Patient-Reported Outcome Measurement Information System (PROMIS) Better Reflects the Impact of Length of Stay and the Occurrence of Complications Within 90 Days Than Legacy Outcome Measures for Lumbar Degenerative Surgery. *Int J Spine Surg*. 2021;15(1):82-86. doi: 10.14444/8011.
100. Horn ME, Reinke EK, Couce LJ, Reeve BB, Ledbetter L, George SZ. Reporting and utilization of Patient-Reported Outcomes Measurement Information System® (PROMIS®) measures in orthopedic research and practice: a systematic review. *J Orthop Surg Res*. 2020;15(1):553. doi: 10.1186/s13018-020-02068-9.
101. Horn ME, Reinke EK, Yan X, et al.. Use of Patient-Reported Outcomes Measurement Information System (PROMIS) measures to characterise health status for patients seeking care from an orthopaedic provider: a retrospective cohort study. *BMJ Open*. 2021;11(9):e047156. doi: 10.1136/bmjopen-2020-047156.
102. Jenkins NW, Parrish JM, Brundage TS, Hrynewycz NM, Singh K. Association of Preoperative PROMIS Scores With Short-term Postoperative Improvements in Physical Function After Minimally Invasive Transforaminal Lumbar Interbody Fusion. *Neurospine*. 2020;17(2):417-425. doi: 10.14245/ns.2040048.024.
103. Jenkins NW, Parrish JM, Hrynewycz NM, Brundage TS, Singh K. Longitudinal Evaluation of Patient-Reported Outcomes Measurement Information System for Back and Leg Pain in Minimally Invasive Transforaminal Lumbar Interbody Fusion. *Neurospine*. 2020;17(4):862-870. doi: 10.14245/ns.1938398.199. Epub 2020 Dec 31. PMID: 33401864; PMCID: PMC7788402.
104. Parrish JM, Jenkins NW, Hrynewycz NM, Brundage TS, Singh K. The influence of gender on postoperative PROMIS physical function outcomes following minimally invasive transforaminal lumbar interbody fusion. *J Clin Orthop Trauma*. 2020;11(5):910-915. doi: 10.1016/j.jcot.2020.04.007.
105. Parrish JM, Jenkins NW, Hrynewycz NM, Brundage TS, Singh K. The Relationship Between Preoperative PROMIS Scores With Postoperative Improvements in Physical Function After Anterior Cervical Discectomy and Fusion. *Neurospine*. 2020 Jun;17(2):398-406. doi: 10.14245/ns.1938352.176. Epub 2020 Feb 5. PMID: 32054141; PMCID: PMC7338965.
106. Passias PG, Horn SR, Segreto FA, et al. ODI Cannot Account for All Variation in PROMIS Scores in Patients With Thoracolumbar Disorders. *Global Spine J*. 2020;10(4):399-405. doi: 10.1177/2192568219851478.
107. Pennings JS, Khan I, Davidson CA, et al. Using PROMIS-29 to predict Neck Disability Index (NDI) scores using a national sample of cervical spine surgery patients. *Spine J*. 2020;20(8):1305-1315. doi: 10.1016/j.spinee.2020.04.028.
108. Rijk L, Kortlever JTP, Tipton GW Jr, Ring D, Queralto MV; Austin Spine Study Group. Is It Time to Replace the Oswestry Index With PROMIS Physical Function Computer Adaptive Test? *Arch Phys Med Rehabil*. 2020;101(9):1549-1555. doi: 10.1016/j.apmr.2020.03.021.
109. Vaishnav AS, Gang CH, Iyer S, McAnany S, Albert T, Qureshi SA. Correlation between NDI, PROMIS and SF-12 in cervical spine surgery. *Spine J*. 2020;20(3):409-416. doi: 10.1016/j.spinee.2019.10.017.
110. Young K, Steinhaus M, Gang C, et al. The Use of Patient-Reported Outcomes Measurement Information System in Spine: A Systematic Review. *Int J Spine Surg*. 2021;15(1):186-194. doi: 10.14444/8024.

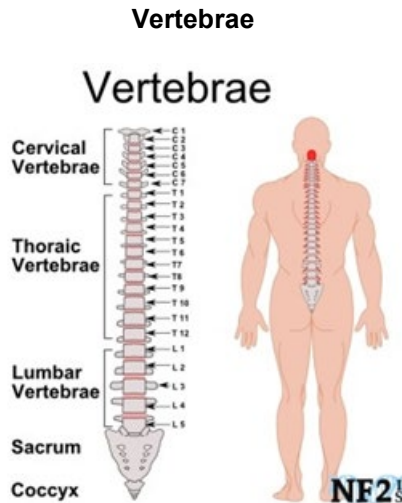
11/2022 MPC:

No new references.

11/2023 MPC:

No new references.

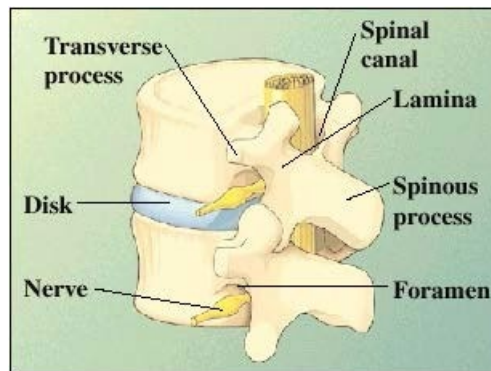
Appendix 1



Source:

https://www.google.com/search?q=discs+in+the+lumbar+spine&biw=1152&bih=590&tbm=isch&imgil=xOFrypCkaq1UIM%253A%253BNdT07YncnEFVoM%253Bhttp%25253A%25252F%25252Fwww.coloradospineinstitute.com%25252Fsubject.php%25253Fpn%2525253Dcond-degenerative-disc-5&source=iu&pf=m&fir=xOFrypCkaq1UIM%253A%252CNdT07YncnEFVoM%252C_&usg=9xvZUFBwoQVpq8IIWW2Au429ZBY%3D&ved=0ahUKEwjlrMKPgOzOAhUQ_mMKHVNSAdEQyjcIOA&ei=8vvGV8jrPJD8jwPTpIWIDQ#tbn=isch&q=number+of+discs+in+the+lumbar+spine&imgrc=le18Zj9Oojx1-M%3A



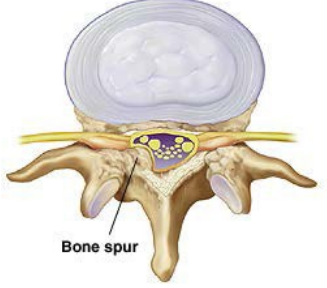

Vertebrae Structure



- There are five vertebrae comprising the lumbar spine, L1 – L5.
- The lamina of each vertebra forms the back of the spinal canal.
- A foramen is a small opening. This is where a nerve leaves the spinal canal.
- The transverse process is the wing of bone on either side of each vertebra.
- The spinous process is the part of each vertebra you can feel through your skin.
- A disk lies between each of the vertebrae.

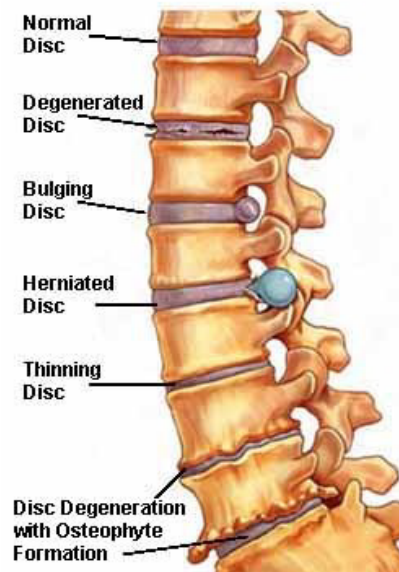
Source: University of Minnesota. <http://www.uofmmmedicalcenter.org/HealthLibrary/Article/84747>. May 2, 2013.

Causes of Lumbar Pain

 <p>Contained bulging disc: the soft nucleus is protruding outward and compressing nerve root.</p>	 <p>Extruded, ruptured disc: the firm annulus has torn, letting the soft center squeeze through to compress nerve root.</p>
 <p>Bone spur</p> <p>Stenosis results when bone spurs (osteophytes) narrow the foramen or spinal canal. This also puts pressure on nerves.</p>	 <p>Worn disk</p> <p>Spondylolisthesis: vertebrae become unstable and slip forward. Slippage can irritate nerves & joints, and can also worsen stenosis.</p>

Source: University of Minnesota. <http://www.uofmmedicalcenter.org/HealthLibrary/Article/85889>. May 2, 2013.

Examples of Disc Problems



Source: <http://www.spineuniverse.com/conditions/neck-pain/degenerative-cervical-spine-disorders>

Appendix 2

Grades of Spondylolisthesis

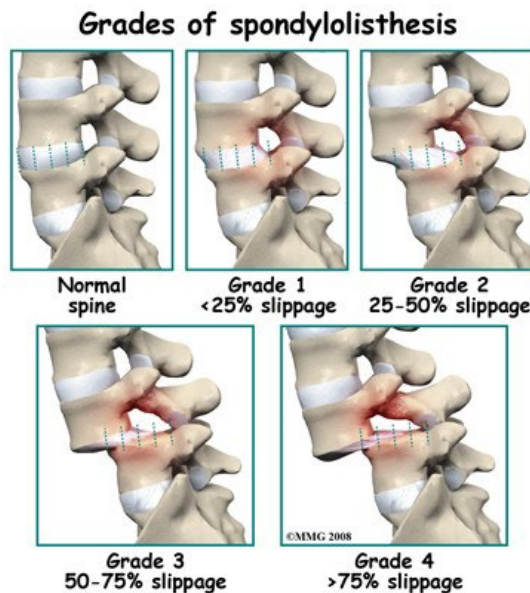
The most common grading system for spondylolisthesis is the Meyerding grading system for severity of slip, with grade 1 being least advanced, and grade 5 being most advanced.

To determine the grade of spondylolisthesis, or slippage, the disc is divided in quarters. The grade is equal to the number of quarters of slippage. If there is no slippage, the grade is zero. If the slippage is equal to one quarter of the total width of the disc, the slippage is grade one. If the slippage is three quarters of the width of a disc, it is a grade three spondylolisthesis. If the slippage is more than four quarters (the whole disc space) then it is called a grade 5. In a grade 5 spondylolisthesis, the spine is completely dislocated.

Grading is calculated by measuring how much a vertebral body has slipped forward over the body beneath it. It is based upon measurements on lateral X-ray of the distance from the posterior edge of the superior vertebral body to the posterior edge of the adjacent inferior vertebral body. This distance is then reported as a percentage of the total superior vertebral body length:

GRADE	Percentage of Total Superior Vertebral Body Length
1	25% of vertebral body has slipped forward
2	50% of vertebral body has slipped forward
3	75% of vertebral body has slipped forward
4	100% of vertebral body has slipped forward
5	Vertebral body completely fallen off (i.e., spondyloptosis)

Source: Vokshoor A. Spondylolisthesis, Spondylolysis, and Spondylosis. eMedicine form WebMD. Last updated June 2010. Available at: <http://emedicine.medscape.com/article/1266860-overview>. Accessed July 26, 2010.



Appendix 3

Oswestry Disability Index (ODI)

Version 2.1a

This questionnaire is designed to provide information as to how your back (or leg) trouble affects your ability to manage in everyday life.

Please answer every section. Mark one box only in each section that most closely describes you today.

Section 1 - Pain intensity

I have no pain at the moment.

The pain is very mild at the moment.

The pain is moderate at the moment. The pain is fairly severe at the moment. The pain is very severe at the moment.

The pain is the worst imaginable at the moment.

Section 2 - Personal care (washing, dressing, etc.)

I can look after myself normally without causing extra pain. I can look after myself normally but it is very painful.

It is painful to look after myself and I am slow and careful. I need some help but manage most of my personal care. I need help every day in most aspects of self care.

I do not get dressed, wash with difficulty and stay in bed.

Section 3 - Lifting

I can lift heavy weights without extra pain.

I can lift heavy weights but it gives extra pain.

Pain prevents me from lifting heavy weights off the floor but I can manage if they are conveniently positioned, e.g. on a table.

Pain prevents me from lifting heavy weights but I can manage light to medium weights if they are conveniently positioned.

I can lift only very light weights.

I cannot lift or carry anything at all.

Section 4 - Walking

Pain does not prevent me walking any distance.

Pain prevents me walking more than one mile.

Pain prevents me walking more than a quarter of a mile. Pain prevents me walking more than 100 yards.

I can only walk using a stick or crutches.

I am in bed most of the time and have to crawl to the toilet.

Section 5 - Sitting

I can sit in any chair as long as I like.

I can sit in my favourite chair as long as I like.

Pain prevents me from sitting for more than 1 hour.

Pain prevents me from sitting for more than half an hour. Pain prevents me from sitting for more than 10 minutes. Pain prevents me from sitting at all.

Section 6 - Standing

I can stand as long as I want without extra pain.

I can stand as long as I want but it gives me extra pain.

Pain prevents me from standing for more than 1 hour.

Pain prevents me from standing for more than half an hour.

Pain prevents me from standing for more than 10 minutes.

Pain prevents me from standing at all.

Section 7 - Sleeping

My sleep is never disturbed by pain.

My sleep is occasionally disturbed by pain.

Because of pain I have less than 6 hours sleep.
Because of pain I have less than 4 hours sleep.
Because of pain I have less than 2 hours sleep.
Pain prevents me from sleeping at all.

Section 8 - Sex life (if applicable)

My sex life is normal and causes no extra pain.
My sex life is normal but causes some extra pain. My sex life is nearly normal but is very painful.
My sex life is severely restricted by pain.
My sex life is nearly absent because of pain.
Pain prevents any sex life at all.

Section 9 - Social life

My social life is normal and causes me no extra pain.
My social life is normal but increases the degree of pain.
Pain has no significant effect on my social life apart from limiting my more energetic interests, e.g. sport, etc.
Pain has restricted my social life and I do not go out as often.
Pain has restricted social life to my home. I have no social life because of pain.

Section 10 - Travelling

I can travel anywhere without pain.
I can travel anywhere but it gives extra pain.
Pain is bad but I manage journeys over two hours.
Pain restricts me to journeys of less than one hour.
Pain restricts me to short necessary journeys under 30 minutes.
Pain prevents me from travelling except to receive treatment

Scoring & Interpretation:

The 6 statements are scored from 0 to 5 with the first statement scoring 0 through to the last at 5. If more than one box is marked in each section, take the highest score.

The ODI score (index) is calculated as (total score/(5 x number of questions answered) x 100

The disability scores are interpreted as follows: 0 to 20%, minimal disability; 20 to 40%, moderate disability; 40 to 60%, severe disability; 60 to 80%, crippled; and 80 to 100%, total incapacitation.

References

1. Fairbank JC, Couper J, Davies JB, O'Brien JP. The Oswestry low back pain disability questionnaire. *Physiotherapy*. 1980. 66(8):271-3.
2. Fairbank J, Pynsent P. The Oswestry Disability Index. *Spine*. 2000;25:2940-2953.
3. Official ODI Website - maintained by the original author, Jeremy Fairbanks.
Available at: <http://www.orthosurg.org.uk/odi/>

Appendix 4

Demineralized Bone (DBM) Matrix Products

Not intended as all-inclusive list

Source Company	DBM Product Name	Available Forms	FDA Addressed Uses
Allosource®	AlloFuse®	Putty, gel, paste	Bone void filler, bone graft extender in extremities, pelvis, and spine.
Baceterin International, Inc./XTANT Medical	OsteoSelect® Osteosponge®	Putty Block, disc, strip, filler	Bone void filler in extremities, pelvis, and posterolateral spine. Non 510(k) regulated – nonmanipulated substance
Lattice Biologics, Ltd	H-GENIN™	Putty, crush-mix, spongy blocks, powder	Non 510(k) regulated – nonmanipulated substance
Biomet/Zimmer Biomet	InterGro DBM®	Putty	Bone void filler in extremities, pelvis, and spine, bone graft extender in spine
Integra™ Orthobiologics/IsoTis Orthobiologics	Accel Connexus®	Putty	Bone void filler in extremities and pelvis, bone graft extender in extremities, pelvis and spine
	Accel Evo3™	Putty	Bone void filler in extremities, pelvis and posterolateral spine, bone graft extender in extremities, pelvis, and spine
	Accel TBM®	Strip	Bone void filler in extremities and pelvis, bone graft extender in extremities, pelvis, and spine
	DynaGraft™	Putty, gel	Bone void filler in extremities and pelvis, bone graft extender in extremities, pelvis, and spine
	OrthoBlast™ II	Putty, paste	Bone void filler in extremities and pelvis, bone graft extender in extremities, pelvis, and spine
LifeNet Health®	Optium®	Putty, gel	Bone void filler in extremities, pelvis, and spine
Medtronic	Progenix Putty	Putty	Bone void filler in extremities, pelvis, and spine
	DBX	Putty, paste, mix, strip	Bone void filler in extremities and pelvis
	GRAFTON®	Gel, flex, putty, matrix, CRUNCH®, orthoblend, strips, paste	Bone void filler and bone graft extender in extremities, pelvis, and spine
	Magnifuse DMB Matrix	DBM fibers and surface-demineralized chips	Bone void filler in Bone void filler in extremities and pelvis
RTI Surgical®, Inc.	BioSet DMB	Paste, strip, disc, with or without cancellous chips	Bone void filler in extremities, pelvis, and spine
Wright™ Medical Technology	ALLMATRIX®	Putty, provided in powder form	Bone void filler in extremities and pelvis, bone graft extender in spine
Zimmer	Puros® DBM	Putty, putty with cortico-cancellous chips	Non 510(k) regulated – nonmanipulated substance

Reference document: Shehadi JA, Elzein SM. Review of commercially available demineralized bone matrix products for spinal fusions: A selection paradigm. *Surg Neurol Int.* 2017;8:203.